

Impression

Matthew Seebachan

Age: 33 Height: 5'9" Weight: 126 lb

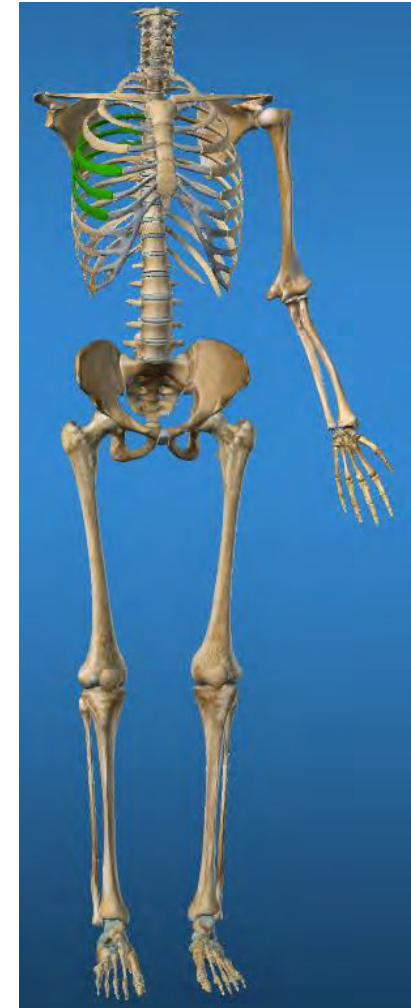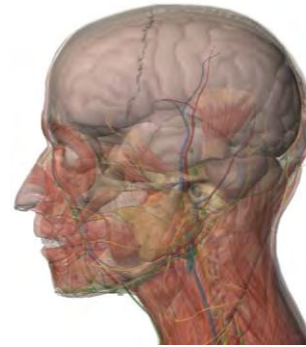
PLAINTIFF'S
EXHIBIT

40-A

DC-15-09782

exhibits1c1er.com

1. GCS=14 (14b:2) [12/21/13]
2. Laceration in forehead going from eyebrow to hairline (doc 14b:2) [12/21/13]
3. Forehead laceration (14c:2) [9/25/14]
4. Deformity to L elbow and open fx (doc 14b:2) [12/21/13]
5. Bilateral internal carotid artery dissection (doc 14c:2) [9/25/14]
6. L humerus fx (doc 14c:2) [9/25/14]
7. R rib fx 4-6 and 8 (doc 14c:2) [9/25/14]
8. L radius fx (doc 14c:2) [9/25/14]
9. Bilateral carotid dissection (14c:2) [9/25/14]
10. Acute respiratory failure (doc 14c:2) [9/25/14]
11. Olecranon fx (doc 14m:1) [1/8/14]
12. Open R calcaneal fx (doc 14m:1) [1/8/14]
13. Closed L calcaneal fx (doc 14m:1) [1/8/14]



Impression

Marcia Seebachan

Age: 29 Height: 5'8" Weight: 172 lb

PLAINTIFF'S
EXHIBIT

40-B

DC-15-09782

exhibitsite.com

1. GCS=10 (doc 15g:71)
2. Atlanto occipital dissociation (doc 15f:16) [1/3/14]
3. Blunt neck trauma with asymptomatic carotid dissections (doc 15f:15)
4. Bilateral carotid artery dissections with initial flap (doc 15f:16) [1/3/14]
5. Transected thoracic aorta distal to L subclavian (doc 15f:24) [12/21/13]
6. Bilateral pulmonary contusions (doc 15f:16) [1/3/14]
7. Bilateral hemothoraces (doc 15f:24) [12/21/13]
8. Sternal fx (doc 15f:19) [12/21/13]
9. R distal radius fx (doc 15f:16) [1/3/14]
10. Comminuted and slightly displaced mid ulnar fx (15g:31)
11. Bilateral renal contusions (doc 15f:16) [1/3/14]
12. Bilateral superior rami with R inferior rami fx (doc 15f:19)
13. L femur fx (doc 15f:24) [12/21/13]
14. Disrupted R sacroiliac joint (doc 15g:30)
15. Anterior to posterior compression fx, type 2 of pelvis (doc 15f:16) [1/3/14]
16. Fx of 3rd metatarsal of L foot (doc 15g:15)
17. Avulsion fx of distal 5th metatarsal on L foot (doc 15g:15)
18. Fx proximal 4-5 toes on L foot (doc 15g:34)

